



International Journal of Medical Anesthesiology

E-ISSN: 2664-3774
P-ISSN: 2664-3766
www.anesthesiologypaper.com
IJMA 2022; 5(1): 28-29
Received: 17-10-2021
Accepted: 03-12-2021

Dr. Reshma P
Postgraduate, Department of
Anaesthesiology, Saveetha
Medical College and Hospital,
Saveetha Nagar, Thandalam,
Chennai, Tamil Nadu, India

Dr. Navaneetha Krishnan
Professor, Department of
Anaesthesiology, Saveetha
Medical College and Hospital,
Saveetha Nagar, Thandalam,
Chennai, Tamil Nadu, India

Dr. Lakshmi R
Professor, HOD, Department
of Anaesthesiology, Saveetha
Medical College and Hospital,
Saveetha Nagar, Thandalam,
Chennai, Tamil Nadu, India

Corresponding Author:
Dr. Reshma P
Postgraduate, Department of
Anaesthesiology, Saveetha
Medical College and Hospital,
Saveetha Nagar, Thandalam,
Chennai, Tamil Nadu, India

Anaesthetic management of tongue cancer

Dr. Reshma P, Dr. Navaneetha Krishnan and Dr. Lakshmi R

DOI: <https://doi.org/10.33545/26643766.2022.v5.i1a.339>

Abstract

Tongue is the most common site of oral cancer which is primarily a disease of epithelial origin. Cancer tongue patients have difficult airway. Proper management in the perioperative period will decrease morbidity and mortality. We report a case of carcinoma tongue on the right lateral aspect which was managed efficiently.

Keywords: Oral cancer, squamous cell carcinoma, difficult airway

Introduction

Oral cancer is sixth most common cancer worldwide. Although HPV has recently been found to be associated with oral cancer, other factors such as tobacco and gutka chewing that are more common in India cannot be neglected. Surgical management is the first choice for oral cancer treatment. Patients exposed to radiation as the primary modality of therapy for oral cancer are likely to have limited neck movements and extension difficulties with restricted mouth opening. Considering these factors, appropriate detailed preoperative evaluation and anaesthetist skill and awareness will reduce morbidity and mortality. We report airway management of patient with growth on right lateral aspect of the tongue.

Case Report

A 78-year-old man presented with 4 months history of growth in the right lateral aspect of tongue 4*3 cm which had been progressively increasing in size. No other positive history was noted. Right level II & III neck nodes palpable.

Laboratory investigations were unremarkable. CT neck revealed ill-defined iso dense thickening in right lateral border of anterior 2/3rd of tongue extending to the floor of mouth. Multiple enhancing prominent and enlarged necrotic and non-necrotic neck nodes. FNAC from the swelling revealed smear positive for malignancy, features of metastatic squamous cell carcinomas deposits. Partial glossectomy with MRND was planned and patient was referred for Preanaesthetic check-up.

General physical examination was unremarkable. Patient's airway assessment revealed Mallampati score 4 with normal neck movements and mild restricted mouth opening. Bilateral nares were patent and there was no nasal septum deviation. In view of above mentioned findings, we planned to perform general anaesthesia with nasotracheal intubation. Procedure was explained to patient and informed consent including consent for tracheostomy, in case of emergency, was taken.

Pre-operative fasting was observed for 8 hours. In the operating room, he was connected to ASA standard monitor. Wide bore iv line secured. Difficult airway equipments and FOB were kept ready. Premedication with inj.glycopyrrolate 0.2 mg iv. Preoxygenation with 100% oxygen was done for 3 min and induced with inj.fentanyl 100 mcg and inj.propofol 100mg. After ascertaining BMV, inj.vecuronium 6mg was given. Using marshall video laryngoscope, with good visualization of epiglottis and vocal cords (Cormack II), patient was intubated with 7 size nasal RAE ETT through right nostril. Anaesthesia was maintained with O₂ and N₂O (50%:50%), isoflurane and intermittent muscle relaxant doses.

Throat pack done and nasogastric tube was inserted.

Intra operatively, adequate analgesia (inj.morphine 4mg), iv fluids was given & urine output was adequate. No major blood loss.

At the end of the surgery, throat pack removed. Patient was on spontaneous ventilation. After thorough oral suctioning and adequate reversal with 5ml of Inj. Myopyrrolate, patient extubated. The patient remained stable in post-anaesthetic care unit and later shifted to ward.

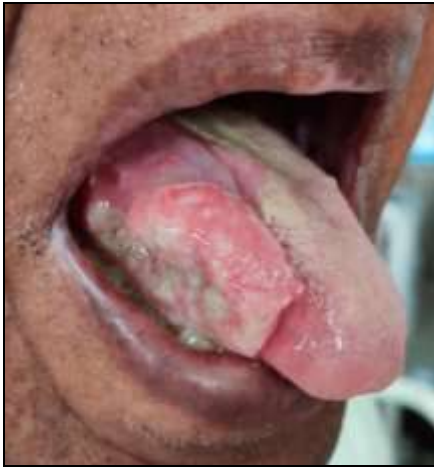

Fig 1: Right Lateral Border CA Tongue

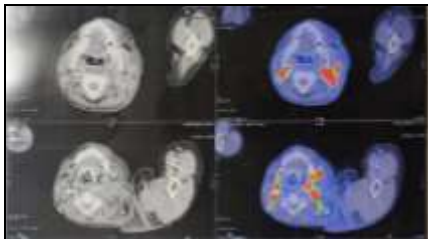


Fig 2: PET scan view of CA Tongue

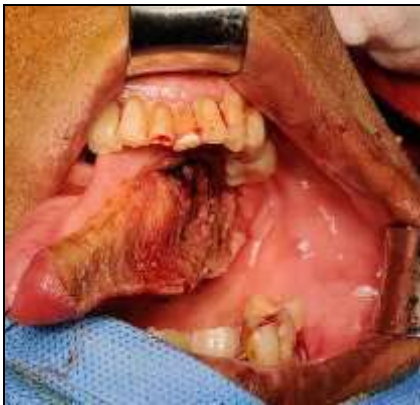

Fig 3: Hemiglossectomy

Discussion

Tongue cancer is one of the main types of oral malignant tumours. Immediate tongue reconstruction and radical operation is the common treatment.

Anaesthetic management depends upon size, location and surgical approach to provide proper exposure of the tumor and distortion of the airway caused by the tumor. The anaesthetic concerns are difficulties in perioperative airway management as both extubation and intubation can be difficult, leading to a sympathetic surge in anaesthetist and further problems [2].

Hence, proper evaluation and planning and discussion with surgeon are needed to avoid unnecessary complications. Symptoms such as loss or change in voice, dysphagia, breathlessness or wheeze should warn the anaesthetist of potential airway problem [3].

In study conducted by Mallampati *et al.* to predict clinical sign to predict difficult intubation, it was revealed that tongue is the single structure in the mouth that affects the accessibility of the laryngeal inlet by direct or indirect laryngoscopy.

Therefore, detailed airway assessment warrants specialist examination with IDL in addition to detailed history, examination, and CT of the tumor to predict how easily the airway will be managed or formally intubated.

In our case, 4*3cm tumor located at right lateral aspect of tongue. No history of voice change or difficulty in swallowing. There was minimal blood loss. After ensuring meticulous haemostasis and complete return of airway reflexes trachea was extubated. Patient did not develop any edema of tissues of oropharynx or upper airway in postoperative period. The recovery was uneventful.

Conclusion

To conclude, delivery of anaesthesia and tracheal intubation, in patients with oral tumors, is a challenge and requires meticulous preoperative airway assessment including detailed clinical examination, CT scan, and MRI to determine the extent of upper airway involvement. It helps the anaesthesiologist select correct equipment for airway control and optimal plan for anaesthesia.

References

1. Anaesthetic management of schwannoma of the base of the Tongue; Upma B Batra, G Usha; Journal of Anaesthesiology Clinical Pharmacology | April-June 2011;27:2.
2. Anaesthesia for head and neck cancer surgery; Anjum Ahmed- Nusrath; BJA Education. 2017;17(12):383-389.
3. Successful tongue cancer surgery under general anaesthesia in a 99-year-old patient in Okinawa, Japan: A case report and review of the literature; Tesho Maruyama, Toshiyuki Nakasone; DOI: 10.3892/ol.2016.4864