



International Journal of Medical Anesthesiology

E-ISSN: 2664-3774
P-ISSN: 2664-3766
www.anesthesiologypaper.com
IJMA 2022; 5(3): 18-20
Received: 19-04-2022
Accepted: 22-05-2022

Donghee Kang
Department of Anesthesiology
and Pain Medicine, Kosin
University College of Medicine,
Busan, South Korea

Ju-Duck Kim
Department of Anesthesiology
and Pain Medicine, Kosin
University College of Medicine,
Busan, South Korea

Treatment of post-lumbar sympathetic neurolysis neurologic complications using a transforaminal epidural block: A case report

Donghee Kang and Ju-Duck Kim

DOI: <https://doi.org/10.33545/26643766.2022.v5.i3a.356>

Abstract

Background: A lumbar sympathetic ganglion block is useful for controlling neuropathic pain. Although the procedure is relatively safe, the use of chemical neurolytic agents may cause neurological complications. We underwent lumbar sympathetic ganglion neurolysis, and thereafter, neurological complications occurred. There is no specific treatment for neurologic complications after neurolysis using chemical agents, and a patient-specific approach is required. In this case, the pain intensity decreased step-by-step after transforaminal epidural block and interlaminar epidural block. We wrote about this treatment experience.

Case presentation: A 45-year-old male patient underwent closed reduction and external fixation surgery for a left distal tibiofibular fracture and was subsequently diagnosed with complex regional pain syndrome. Lumbar sympathetic ganglion neurolysis was performed for treatment, but sensory loss of the L2 and L3 dermatomes and adductor muscle weakness of the lower leg occurred. Transforaminal epidural block and interlaminar epidural block were repeatedly performed to treat complications, and these procedures helped control the symptoms.

Conclusions: When neurological complications occur after lumbar sympathetic neurolysis, an excellent therapeutic effect can be expected if transforaminal epidural block is used together with palliative treatment.

Keywords: Case report, chemical neurolysis, epidural injections, neuropathic pain, sympathetic nerve block

Introduction

Lumbar sympathetic ganglion blocks (LSGB) have been widely used for years to treat sympathetic nerve-related pain in the lower extremity pain [1]. They have been applied to patients with circulatory insufficiency owing to vascular problems in the lower extremities, and their indications have been extended to diseases such as hyperhidrosis and lymphedema as well as neuropathic pain such as complex regional pain syndrome (CRPS), amputation stump pain, and herpes zoster [2]. Neurolysis is sometimes performed using chemical agents such as phenol or alcohol or methods such as radiofrequency ablation rather than blocks using only local anesthetics to prolong the duration of the effect [1]. Although the procedure is relatively safe, mechanical injuries such as bleeding and renal and ureteric injuries may occur. Additionally, neurological complications such as nerve root injury, genitofemoral neuralgia, neuraxial injection, and paralysis may happen [2].

Neurological complications are related to the spread of the drug used and are most likely to advance to the psoas muscle. The spread of the drug to the psoas muscle may affect the lumbar plexus. Neuralgia can occur when a neurotic agent is used and is most common in the genitofemoral nerve with an occurrence of approximately 6–16% [3]. Additionally, minor sensory loss and motor weakness have been reported to occur at a frequency of 5–6% [3].

There is no specific treatment for neurologic complications after neurolysis using chemical agents, and a patient-specific approach is required. Herein, we report a case with sensory loss of the L2 and L3 dermatomes and adductor muscle weakness of the lower leg after lumbar sympathetic ganglion neurolysis. Moreover, these neurological complications were primarily treated using a transforaminal epidural block (TFEB).

Corresponding Author:
Donghee Kang
Department of Anesthesiology
and Pain Medicine, Kosin
University College of Medicine,
Busan, S. Korea

Case presentation

A 45-year-old male patient underwent closed reduction and external fixation surgery for a left distal tibiofibular fracture 8 years ago. He was diagnosed with CRPS type II 3 years after the surgery owing to persistent pain. For several years, the pain was controlled using analgesics (pregabalin 150mg/day, oxycodone 10mg/day); however, recently, the cold sensation and pain in the left foot and ankle became severe. Therefore, an LSGB was planned. Ethical approval was taken from our institutional review board and consent to participate from patient is taken.

An LSGB was performed using a tunnel vision approach at the left L3 level. In several trials, the contrast medium spread to the posas muscle, however, the final position of the needle was confirmed using a contrast medium was only applied to the lateral part of the spine (Fig 1), and 10 mL of 0.375% ropivacaine was injected. 20 minutes later, the temperature of lower leg and sensation and muscle strength of the thigh were evaluated. Using a skin thermometer attached to both soles, the body temperature of the left sole was confirmed to be increased by 1.5°. After no numbness or muscle weakness was observed in the thigh, 3 mL of dehydrated alcohol was injected. Mild motor weakness of the left lower leg was observed on the day of the procedure; however, recovery occurred after 1 h, and the patient returned home. One week after the procedure, the patient visited an outpatient clinic and complained of sensory loss and neuropathic pain in the left L2 and L3 dermatomes. However, the coldness and pain in the left foot and ankle, which were initially painful, had almost disappeared. The pain level of the anterior aspect of the thigh was 7/10 on the numerical rating scale (NRS), and the motor grade of adductor muscles were 4/5 (the muscle can move the joint it crosses through a full range of motion against moderate resistance). At the outpatient clinic that day, ketamine (50 mg) and lidocaine (200 mg) were administered intravenously, and pregabalin was increased to 600 mg/day.

A week later, when the patient visited the outpatient clinic again, the symptoms persisted; therefore, hospitalization was planned. After hospitalization, pregabalin was temporarily increased to 750 mg/day, and tapentadol 100 mg/day was added to oxycodone, the original analgesic. After hospitalization, ketamine 50 mg and lidocaine 200 mL were continued intravenously. This treatment was repeated every 2 days during the hospital stay. Rehabilitation treatment was performed concurrently; however, it was discontinued because of pain. As the pain and muscle weakness persisted, a TFEB using 5 mg of dexamethasone and 5ml of 0.2% ropivacaine was performed on the L2 and L3 nerve roots. After the procedure, pain improved to approximately 5/10 on the NRS, and a TFEB were repeated two more times to alleviate the remaining symptoms. In the second and third procedures, the dose of dexamethasone was reduced to 2 mg. After repeated treatment using nerve blocks, oral administration, and ketamine and lidocaine intravenous therapy for 2 weeks, the patient's pain improved to approximately 1–2/10 on the NRS. The decrease in muscle strength did not completely recover; however, it was improved compared to that at the first visit to the clinic. The original CRPS pain continued to improve after LSGB; therefore, after adjusting the oral medications, the patient was discharged from the hospital and recommended to undergo follow-up on an outpatient basis.

Discussion

Although an LSGB is a relatively safe procedure, neurologic complications may occur when neurolysis using chemical agents is used to prolong the treatment effect. These neurological symptoms can cause severe neuralgia and motor weakness and can persist for long; therefore, it is best to prevent them by providing accurate treatment using C-arm radiography or ultrasonography. Given that the lumbar sympathetic chain runs on the anteromedial aspect of the psoas muscle, and the lumbar plexus runs behind the psoas muscle, the psoas muscle requires attention during LSGB. In particular, complication occurs most frequently in the genitofemoral nerve because it originates from the anteromedial surface of the psoas muscle [2]. Hong et al. presented that psoas muscle injection was the least frequent when performed at L2 level and recommended a method of distributing small amounts to multiple levels [4]. Another study reported that when the procedure was performed using a small amount of chemical agents on the left side, targeting the lower third L4 vertebral body, respectively, the success rate of the procedure was high [5]. If it was performed on the right side, the success rate was high when targeting the lower margin of the L3 vertebral body [5]. Although the frequency and type of complications may differ depending on the procedure site, it is recommended to use a small amount of drug, and the effect is assumed to be better when treatment is applied at two levels rather than one. Cousins et al. reported that neurological complications respond relatively well to narcotic analgesics and transcutaneous stimulation [6]. However, in some cases, the intensity of pain may be severe, and the duration of pain may last more than 2 months [6]. The patient in this case also had severe pain with an intensity of 7/10 on the NRS and complained of mild motor weakness (motor grade 4/5) and sensory changes. In this case, it is thought that some of the neurolytic agents leaked into the L2 and L3 nerve roots. A prompt intervention was necessary; therefore, pregabalin was initially increased to the maximum daily dose, and intravenous therapy was started with ketamine 50 mg and lidocaine 200 mg. Ketamine is a non-competitive antagonist of the N-methyl-D-aspartic acid receptor. Although the therapeutic mechanism is unclear, ketamine has been clinically applied to various neuropathic pain disorders and works mainly by modulating ascending nociceptive transmission [7]. Lidocaine is a sodium channel blocker that reduces neuropathic pain caused by the abnormal activation of sodium channels [8]. No long-term analgesic effect have been reported in patients with neuropathic pain [9], however short-term pain relief is anticipated; therefore, lidocaine was used in the patient in this case [8].

Epidural injections of steroids help control pain by stabilizing the nerve membrane and inhibiting the sensitization of dorsal horn neurons [10]. Bush et al. reported that epidural injection in cases of sciatica caused by lumbar nerve root compromise was helpful in pain control and lifestyle improvement [11]. In our case, the patient experienced sensory loss and motor changes in the L2 and L3 dermatomes; therefore, the neurolytic agent was assumed to have leaked into the nerve roots, and pain was caused by nerve stimulation. It was expected that by injecting steroids into the epidural space the symptoms of nerve stimulation could be reduced through this mechanism. Methods for epidural injection largely involve caudal, interlaminar, or transforaminal approaches. Among them,

the most suitable approach for controlling radicular pain is the transforaminal approach ^[12]. A TFEB was first performed on the patient, and it was confirmed that pain was reduced from 6/10 to 3/10 on the NRS after the procedure. Thereafter, an interlaminar epidural block and a TFEB were repeated once every 3 days, and pain was finally improved to 1–2/10 on the NRS.

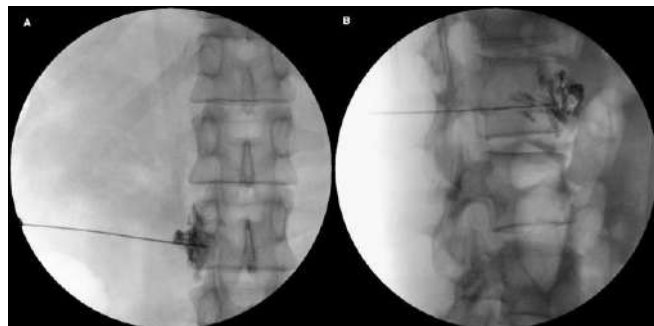


Fig 1: Posterior-anterior(A) and lateral fluoroscopic(B) images show spreading of contrast media in lumbar sympathetic ganglion chain

Conclusion

There is no specific treatment for neurologic complications after neurolysis using chemical agents, and a patient-specific approach is required. In this case, the pain intensity decreased step-by-step after TFEB and interlaminar epidural block, and in particular, the pain reduction effect was the greatest after TFEB. When neurological complications occur after lumbar sympathetic neurolysis, an excellent therapeutic effect can be expected if TFEB is used together with palliative treatment.

Consent for publication

Written informed consent to present, discuss and publish the patient's medical information, management details, and pictures was taken.

Conflict of Interest

Not available

Financial Support

Not available

Reference

1. Abramov R. Lumbar sympathetic treatment in the management of lower limb pain. *Curr Pain Headache Rep.* 2014;18(4):403.
2. Middleton WJ, Chan VW. Lumbar sympathetic block: A review of complications. *Techniques in Regional Anesthesia and Pain Management.* 1998;2(3):137-46.
3. Stanton-Hicks M. Complications of sympathetic blocks for extremity pain. *Techniques in Regional Anesthesia and Pain Management.* 2007;11(3):148-51.
4. Hong JH, Oh MJ. Comparison of Multilevel with Single Level Injection during Lumbar Sympathetic Ganglion Block: Efficacy of Sympatholysis and Incidence of Psoas Muscle Injection. *Korean J Pain.* 2010;23(2):131-6.
5. An JW, Koh JC, Sun JM, Park JY, Choi JB, Shin MJ, et al. Clinical Identification of the Vertebral Level at Which the Lumbar Sympathetic Ganglia Aggregate. *The Korean Journal of Pain.* 2016;29(2):103-9.

6. Cousins MJ, Reeve TS, Glynn CJ, Walsh JA, Cherry DA. Neurolytic Lumbar Sympathetic Blockade: Duration of Denervation and Relief of Rest Pain. *Anaesthesia and Intensive Care.* 1979;7(2):121-35.
7. Maher DP, Chen L, Mao J. Intravenous ketamine infusions for neuropathic pain management: a promising therapy in need of optimization. *Anesthesia & Analgesia.* 2017;124(2):661-74.
8. Attal N, Rouaud J, Brasseur L, Chauvin M, Bouhassira D. Systemic lidocaine in pain due to peripheral nerve injury and predictors of response. *Neurology.* 2004;62(2):218-25.
9. Moulin DE, Morley-Forster PK, Pirani Z, Rohfrisch C, Stitt L. Intravenous lidocaine in the management of chronic peripheral neuropathic pain: a randomized-controlled trial. *Canadian Journal of Anesthesia/Journal canadien d'anesthésie.* 2019;66(7):820-7.
10. Society TKP. *Textbook of Pain Medicine*; c2018. p. 593.
11. Bush K, Hillier S. A controlled study of caudal epidural injections of triamcinolone plus procaine for the management of intractable sciatica. *Spine.* 1991;16(5):572-5.
12. Ackerman WEI, Ahmad M. The Efficacy of Lumbar Epidural Steroid Injections in Patients with Lumbar Disc Herniations. *Anesthesia & Analgesia.* 2007;104(5):1217-22.

How to Cite This Article

Kang D, Kim Ju-Duck. Treatment of post-lumbar sympathetic neurolysis neurologic complications using a transforaminal epidural block: A case report. *International Journal of Medical Anesthesiology.* 2022;5(3):18-20. DOI: <https://doi.org/10.33545/26643766.2022.v5.i3a.356>

Creative Commons (CC) License

This is an open access journal, and articles are distributed under the terms of the Creative Commons Attribution-NonCommercial-ShareAlike 4.0 International (CC BY-NC-SA 4.0) License, which allows others to remix, tweak, and build upon the work non-commercially, as long as appropriate credit is given and the new creations are licensed under the identical terms.